Check for updates

REVIEW

Advanced imaging improves the diagnosis of infective endocarditis

[version 1; peer review: 2 approved]

Daniel Harding, Bernard Prendergast

Department of Cardiology, St Thomas' Hospital, London, UK

v1 **First published:** 29 May 2018, **7**(F1000 Faculty Rev):674
https://doi.org/10.12688/f1000research.13791.1

Latest published: 29 May 2018, **7**(F1000 Faculty Rev):674
https://doi.org/10.12688/f1000research.13791.1

Abstract

Infective endocarditis is a heterogeneous condition whose incidence is rising. Despite advances in surgery and diagnostic methods, one-year mortality has not changed and it remains at 30%. Patients with prosthetic valve and intra-cardiac device–related endocarditis are being seen more frequently and this condition is difficult to diagnose with conventional microbiological and imaging techniques. The modified Duke criteria lack sensitivity in this group and should be supplemented with newer imaging techniques, including 18F-fluorodeoxyglucose positron emission tomography (18F-FDG-PET) and single-photon emission computed tomography (SPECT). In this article, we discuss these techniques and their role in the diagnosis of infective endocarditis.

Keywords

Infective endocarditis, PET, SPECT, Nuclear Imgaing, Cardiology

Open Peer Review

Approval Status ✔ ✔

	1	2
version 1 29 May 2018	✔	✔

Faculty Reviews are review articles written by the prestigious Members of Faculty Opinions. The articles are commissioned and peer reviewed before publication to ensure that the final, published version is comprehensive and accessible. The reviewers who approved the final version are listed with their names and affiliations.

1. **Andrzej Kutarski**, Medical University of Lublin, Lublin, Poland
2. **Francois Rouzet**, Bichat-Claude Bernard Hospital, AP-HP, Paris, France

Any comments on the article can be found at the end of the article.

Corresponding author: Bernard Prendergast (bernard.prendergast@gstt.nhs.uk)

Author roles: Harding D: Writing – Original Draft Preparation; **Prendergast B**: Writing – Review & Editing

Competing interests: No competing interests were disclosed.

Grant information: The author(s) declared that no grants were involved in supporting this work.

Copyright: © 2018 Harding D and Prendergast B. This is an open access article distributed under the terms of the Creative Commons Attribution License, which permits unrestricted use, distribution, and reproduction in any medium, provided the original work is properly cited.

How to cite this article: Harding D and Prendergast B. **Advanced imaging improves the diagnosis of infective endocarditis [version 1; peer review: 2 approved]** F1000Research 2018, **7**(F1000 Faculty Rev):674 https://doi.org/10.12688/f1000research.13791.1

First published: 29 May 2018, **7**(F1000 Faculty Rev):674 https://doi.org/10.12688/f1000research.13791.1

Introduction

Although infective endocarditis (IE) remains a rare condition worldwide, incidence is rising[1] as a combined consequence of the increased number of patients at high risk for the condition (Table 1) and increased nosocomial infection, possibly exacerbated by the impact of reduced use of antibiotic prophylaxis[2]. The high-risk population is likely to expand further with increasing rates of invasive procedures, including percutaneous valve replacement and intra-cardiac electronic device (ICED) implantation[3,4]. Of equal importance, *staphylococcus* now supersedes *streptococcus* as the most frequent causative pathogen and the average age of affected subjects is rising[5]. Therefore, patients are more frail and co-morbid and frequently present with more aggressive forms of the disease. These trends seem likely to offset the benefits associated with earlier diagnosis and more aggressive surgical management. As a result, IE has a one-year mortality exceeding 30%, which has remained unchanged over the past 20 years and is higher than that of many common cancers[6,7].

Table 1. Risk factors for infective endocarditis.

Prosthetic valve replacement (including percutaneous)
Haemodialysis
Long-term intravenous catheters
Immunosuppression
Intravenous drug use
Congenital heart disease
Implantable cardiac electronic device

Diagnosis of IE remains challenging, requiring a high index of clinical suspicion and appropriate investigation of high-risk patients. Both the European Society of Cardiology (ESC) and the American Heart Association recommend use of the modified Duke criteria (Table 2) for the diagnosis of IE[8,9]. Although these criteria remain useful as a diagnostic aid, they are less sensitive in patients with prosthetic valve endocarditis (PVE), ICED infection[10] and IE affecting the right side of the heart. Both major criteria are less sensitive in PVE and ICED: negative blood cultures are common (>20%) and transthoracic echocardiography

Table 2. Modified Duke criteria for the diagnosis of infective endocarditis.

Pathological criteria
Microorganisms on histology or culture of a vegetation or intra-cardiac abscess
Evidence of lesions: vegetation or intra-cardiac access showing active endocarditis on histology
Major clinical criteria
1. Blood cultures positive for infective endocarditis
Typical microorganisms consistent with infective endocarditis from two separate blood cultures:
- *Staphylococcus aureus, viridans streptococci, Streptococcus bovis*, HACEK group, or community-acquired *enterococci* in the absence of a primary focus
OR
Microorganisms consistent with infective endocarditis from persistently positive blood cultures:
- At least two positive blood cultures from samples drawn more than 12 hours apart or all of three or most of at least four separate cultures of blood (with first and last sample more than one hour apart)
OR
Single positive blood culture for *Coxiella burnetii* or phase 1 IgG antibody titre greater than 1:800
2. Evidence of endocardial involvement
Echocardiography positive for infective endocarditis
- Defined by presence of a vegetation, abscess or new partial dehiscence of a prosthetic valve
New valvular regurgitation
- Note: increase or change in pre-existing murmur is not sufficient.
Minor clinical criteria
1. Predisposition: predisposing heart condition and intravenous drug use
2. Fever: temperature >38°C
3. Vascular phenomena: major arterial emboli, septic pulmonary infarcts, mycotic aneurysm, intra-cranial haemorrhages, conjunctival haemorrhages, and Janeway lesions
4. Immunological phenomena: glomerulonephritis, Osler's nodes, Roth spots, and rheumatoid factor
5. Microbiological evidence: positive blood culture that does not meet a major criterion or serological evidence of active infection with organism consistent with infective endocarditis
Diagnosis of endocarditis is definite in the presence of one pathological criterion, two major criteria, one major and three minor criteria, or five minor criteria.
Diagnosis of infective endocarditis is possible in the presence of one major and one minor criterion or three minor criteria.
Modified Duke criteria were originally published by Li and colleagues[11].

(TTE) can miss pacemaker lead involvement and PVE in up to 60% of cases[12,13]. It is also important to note that the Duke criteria were originally designed as a research tool and should not supplant clinical assessment.

Regardless of the chosen diagnostic guideline, it is likely that a greater proportion of patients with PVE and ICED infection will fall under the 'possible' category (Figure 1) (that is, high-risk patients with some clinical features that do not meet the required cutoff indicated by the modified Duke criteria). Although such patients present a considerable diagnostic challenge, they also stand to benefit the most from the cardiovascular imaging advances that have taken place over the past five years.

Transoesophageal echocardiography

Transoesophageal echocardiography (TOE) is the gold-standard second-line imaging modality for IE and features prominently in both European and American guidelines. It has a sensitivity of more than 90% for native valve and more than 85% for prosthetic and device-related endocarditis[13], is a more accurate tool than TTE for assessing intra- and extra-cardiac lead portions[14], and is superior to TTE for detection and characterisation of perforations, abscesses and fistulae[13]. However, TOE is not without weaknesses. Distinction of active infection from post-operative changes limits its use in patients with suspected PVE who have recently undergone surgery. Furthermore, it can be challenging to differentiate vegetation from thrombi and fibrous strands: about 10% of patients undergoing a TOE for unrelated reasons demonstrate a mass or vegetation with no subsequent diagnosis of IE[15]. TOE also has limitations in patients with possible ICED endocarditis. Artefact and acoustic shadowing associated with ICED makes it difficult to fully assess the right side of the heart. Indeed, pacemaker leads can be actively infected with no evidence of vegetation on TOE[14].

Three-dimensional transoesophageal echocardiography

Three-dimensional transoesophageal echocardiography (3D-TOE) is carried out with a multi-plane probe incorporating a 3D matrix array. It generates full-volume datasets that can be manipulated to visualise vegetations and defects in planes and at angles that are not possible with conventional TOE[16]. The technique has particular value in the detection of paravalvular abscess, valve dehiscence,

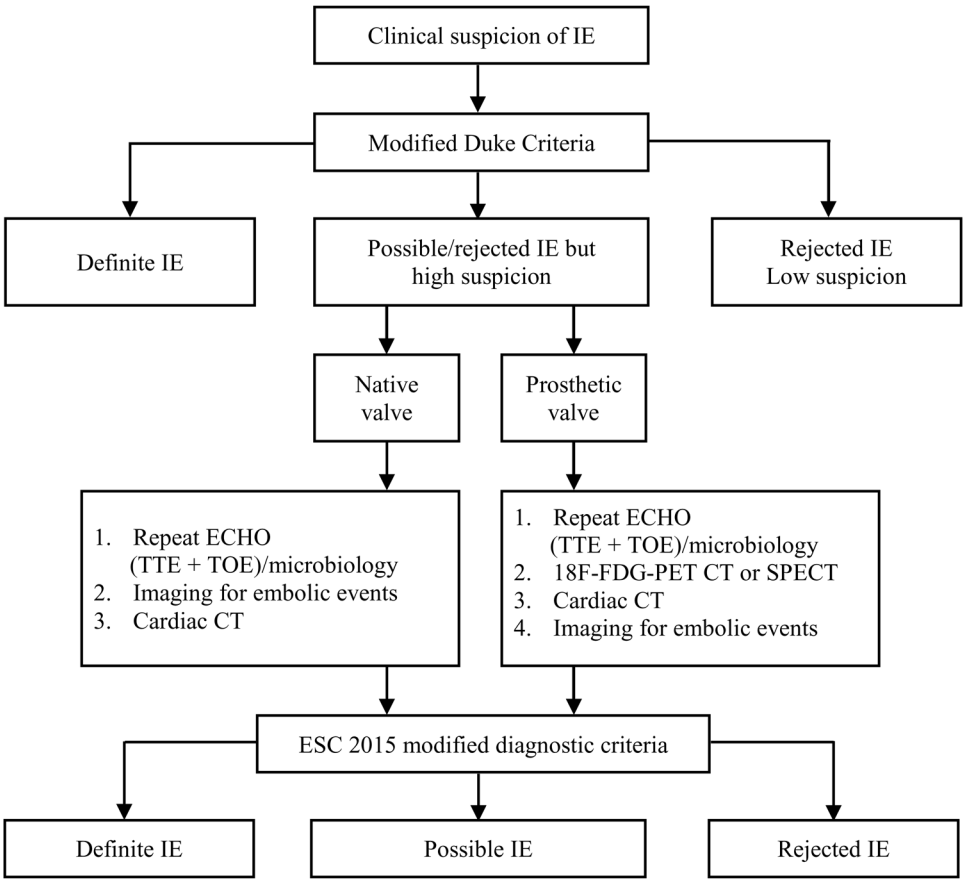

Figure 1. Diagnostic criteria for infective endocarditis. Taken from the 2015 European Society of Cardiology (ESC) guidelines for the management of infective endocarditis (IE)[9]. 18F-FDG PET, 18F-fluorodeoxyglucose positron emission tomography; CT, computed tomography; ECHO, echocardiogram; SPECT, single-photon emission computed tomography; TOE, transoesophageal echocardiography; TTE, transthoracic echocardiography.

regurgitation and perforation[9] and is more specific (but not more sensitive) for the exclusion of IE (up to 100%) when compared with TOE[17]. 3D-TOE may help to identify patients at increased risk of embolism by providing a more accurate assessment of vegetation size[18]. Finally, by providing an 'en-face' valve view, 3D-TOE may facilitate more accurate surgical planning. Currently, studies supporting the use of 3D-TOE in the diagnosis and management of IE are limited by their small number and size and there have been no studies specifically focused on the use of 3D-TOE in PVE or ICED endocarditis. It is also important to note that the low frame rate of 3D-TOE may impair the detection of small vegetations[19]. Therefore, the technique should continue to be used as a supplement to conventional TTE/2D-TOE in most patients.

Multislice computed tomography

Multislice computed tomography (MSCT) is complementary to conventional echocardiography in the diagnosis of IE and indications for its use have been incorporated into the 2014 American College of Cardiology/American Heart Association valvular heart disease guidelines (class IIa, level of evidence B) and the 2015 ESC guidelines on the management of IE[9,20]. MSCT uses ECG gating to eliminate movement artefact during the cardiac cycle and reduce radiation exposure to 2–3 mSv per scan[21]. It is equivalent (and may be superior) to TOE for the delineation of paravalvular anatomy and detection of fistulae and abscess[22] and is superior to TOE for the detection of mycotic aneurysms. Use of MSCT may also reduce the need for invasive imaging by characterising the coronary arteries, aortic valve, root and ascending aorta[23]. It is also less susceptible to prosthetic valve artefact than TOE and therefore is an attractive adjunct in the assessment of suspected PVE. In a group of 28 patients with suspected PVE, the addition of MSCT to routine work-up (including TTE/TOE) resulted in a major diagnostic change in six patients (21%)[23]. Unlike echocardiographic techniques, MSCT has the potential to consolidate the diagnosis of IE by identifying distal embolic complications if the scan window is extended beyond the thorax. Drawbacks include the need for exposure to ionising radiation, use of iodinated contrast and the lack of large studies comparing the technique with conventional echocardiography.

Positron emission tomography

18F-fluorodeoxyglucose positron emission tomography (18F-FDG PET) is a relatively new technique more frequently used in the diagnosis and staging of cancer that shows promise for improved assessment of 'possible' IE according to the modified Duke criteria. The technique highlights areas of increased glucose metabolism corresponding to active inflammation, which can be mapped to conventional computed tomography (CT) datasets to provide anatomical landmarks. Although early studies generated concerns with regard to low sensitivity in native valve IE (<40%), the technique has demonstrated significant value in the diagnosis of PVE and ICED endocarditis[24] (sensitivity of 87% and specificity of 92%)[25]. Supplementing the diagnostic sensitivity of the modified Duke criteria in suspected PVE and ICED endocarditis increased from 52 to 91% in association with the use of 18F-FDG-PET[25], leading to its incorporation into the diagnostic algorithm for high-risk patients with equivocal initial investigations in the 2015 ESC guidelines[9]. Like MSCT, 18F-FDG-PET can detect distant emboli and evidence of metastatic infection, increasing sensitivity relative to TTE and TOE and identify higher-risk patients—those with more metastatic infection—who may benefit from early surgery[26]. 18F-FDG-PET has the advantage over MSCT in that it is normal practice to image the whole skeleton rather than just the thoracic cavity. However, as with all imaging techniques, 18F-FDG-PET results must be interpreted with caution. At present, it is not possible to distinguish a sterile, post-operative inflammatory response from infection. Nor can 18F-FDG-PET differentiate thrombi, soft atherosclerotic plaque or foreign body reactions. Given the high mortality associated with device and valve explantation, 18F-FDG-PET data should always be interpreted with caution, especially in the early post-operative phase[21]. Moreover, sensitivity is low in native valve IE and routine use is not recommended in this group[27].

Single-photon emission computed tomography

Single-photon emission computed tomography (SPECT) is a nuclear technique that measures gamma rays emitted from injected radionucleotides. Multiple 2D plane images are acquired and reconstructed to provide anatomical localisation in 3D. Detection of infection relies on the accumulation of neutrophils in the region of IE and the technique is most sensitive in the acute phase[21]. There have been relatively few large studies evaluating the utility of SPECT in the diagnosis of IE, but multiple case reports and smaller trials suggest benefit in PVE[28–30]. As a result, its use has been incorporated into the 2015 ESC guidelines as an adjunct to repeat TOE/TTE in possible PVE[9]. SPECT was more specific (100% versus 71%) but less sensitive (64% versus 93%) than 18F-FDG-PET CT in a cohort of 39 patients with suspected PVE[30]. However, increased specificity in patients who have undergone recent surgery offers advantages: in a group of 131 patients evaluated with SPECT for suspected IE (including those operated within two months), sensitivity was 90% and specificity was 100%[28]. Conversely, SPECT is more time-consuming than 18F-FDG-PET CT, requires blood handling for preparation of radiopharmaceuticals, and has lower spatial resolution than 18F-FDG-PET CT[16,29]. Sadly, current data are mostly limited to native and prosthetic valve endocarditis, so additional work will need to be carried out to establish the full role of SPECT in suspected ICED endocarditis.

Discussion

The landscape of IE is changing: older and increasingly co-morbid patients with prosthetic material are presenting to hospital with staphylococcal IE that can be difficult to detect by using conventional microbiological and imaging techniques. The modified Duke criteria (Table 1) are neither sensitive nor specific in this cohort, and more patients are left with a diagnosis of 'possible' IE (Figure 1). Previous guidelines have emphasised the use of 2D-TOE and repeat TTE in this group, but these techniques can also be inadequate to confirm/exclude the diagnosis, especially in the presence of a cardiac device or prosthetic valve. The development of 3D-TOE, MSCT and advanced nuclear imaging (18F-FDG-PET CT and SPECT) facilitates an evaluation pathway in this setting. Patients who are at high risk of IE but have an equivocal or negative TTE (or microbiology) can now progress to diagnostic techniques with high sensitivity and specificity to guide their clinical management. These techniques not only

provide local anatomical information in terms of valvular and paravalvular complications but also may strengthen the diagnosis through detection of metastatic infection.

MSCT and 3D-TOE are broadly complementary to conventional diagnostic work-up and may facilitate better surgical planning. In contrast, 18F-FDG-PET CT and SPECT have the potential to determine a diagnosis of IE, even in patients with prosthetic valves and intra-cardiac devices. SPECT is clearly more suitable for patients who have recently undergone surgery as it remains specific, whereas the higher sensitivity and simpler technical aspects of 18F-FDG-PET CT make it an attractive second-line test in patients with a high clinical likelihood of IE and normal or equivocal initial imaging findings. The increasing role and importance of nuclear medicine in the diagnosis and management of IE provide further support for a hub-and-spoke model of service provision, and complex cases are best managed in tertiary reference centres that have the experience and technical resources to offer these techniques routinely.

Competing interests

The authors declare that they have no competing interests.

Grant information

The author(s) declared that no grants were involved in supporting this work.

References

F F1000 recommended

1. F Pant S, Patel NJ, Deshmukh A, *et al.*: **Trends in infective endocarditis incidence, microbiology, and valve replacement in the United States from 2000 to 2011.** *J Am Coll Cardiol.* 2015; **65**(19): 2070–6.
PubMed Abstract | Publisher Full Text | F1000 Recommendation
2. Dayer MJ, Jones S, Prendergast B, *et al.*: **Incidence of infective endocarditis in England, 2000-13: a secular trend, interrupted time-series analysis.** *Lancet.* 2015; **385**(9974): 1219–28.
PubMed Abstract | Publisher Full Text | Free Full Text
3. F Ludman PF, Moat N, de Belder MA, *et al.*: **Transcatheter aortic valve implantation in the United Kingdom: temporal trends, predictors of outcome, and 6-year follow-up: a report from the UK Transcatheter Aortic Valve Implantation (TAVI) Registry, 2007 to 2012.** *Circulation.* 2015; **131**(13): 1181–90.
PubMed Abstract | Publisher Full Text | F1000 Recommendation
4. Research NIoCO: **National Audit of Cardiac Rhythm Management Devices. 2015-2016.**
Reference Source
5. F Murdoch DR, Corey GR, Hoen B, *et al.*: **Clinical presentation, etiology, and outcome of infective endocarditis in the 21st century: the International Collaboration on Endocarditis-Prospective Cohort Study.** *Arch Intern Med.* 2009; **169**(5): 463–73.
PubMed Abstract | Publisher Full Text | Free Full Text | F1000 Recommendation
6. F Lalani T, Chu VH, Park LP, *et al.*: **In-hospital and 1-year mortality in patients undergoing early surgery for prosthetic valve endocarditis.** *JAMA Intern Med.* 2013; **173**(16): 1495–504.
PubMed Abstract | Publisher Full Text | F1000 Recommendation
7. F Cresti A, Chiavarelli M, Scalese M, *et al.*: **Epidemiological and mortality trends in infective endocarditis, a 17-year population-based prospective study.** *Cardiovasc Diagn Ther.* 2017; **7**(1): 27–35.
PubMed Abstract | Publisher Full Text | Free Full Text | F1000 Recommendation
8. F Baddour LM, Wilson WR, Bayer AS, *et al.*: **Infective Endocarditis in Adults: Diagnosis, Antimicrobial Therapy, and Management of Complications: A Scientific Statement for Healthcare Professionals From the American Heart Association.** *Circulation.* 2015; **132**(15): 1435–86.
PubMed Abstract | Publisher Full Text | F1000 Recommendation
9. F Habib G, Lancellotti P, Antunes MJ, *et al.*: **2015 ESC Guidelines for the management of infective endocarditis: The Task Force for the Management of Infective Endocarditis of the European Society of Cardiology (ESC). Endorsed by: European Association for Cardio-Thoracic Surgery (EACTS), the European Association of Nuclear Medicine (EANM).** *Eur Heart J.* 2015; **36**(44): 3075–128.
PubMed Abstract | Publisher Full Text | F1000 Recommendation
10. Prendergast BD: **Diagnostic criteria and problems in infective endocarditis.** *Heart.* 2004; **90**(6): 611–3.
PubMed Abstract | Publisher Full Text | Free Full Text
11. Li JS, Sexton DJ, Mick N, *et al.*: **Proposed modifications to the Duke criteria for the diagnosis of infective endocarditis.** *Clin Infect Dis.* 2000; **30**(4): 633–8.
PubMed Abstract | Publisher Full Text
12. Cahill TJ, Prendergast BD: **Infective endocarditis.** *Lancet.* 2016; **387**(10021): 882–93.
PubMed Abstract | Publisher Full Text
13. Cahill TJ, Baddour LM, Habib G, *et al.*: **Challenges in Infective Endocarditis.** *J Am Coll Cardiol.* 2017; **69**(3): 325–44.
PubMed Abstract | Publisher Full Text
14. Sandoe JA, Barlow G, Chambers JB, *et al.*: **Guidelines for the diagnosis, prevention and management of implantable cardiac electronic device infection. Report of a joint Working Party project on behalf of the British Society for Antimicrobial Chemotherapy (BSAC, host organization), British Heart Rhythm Society (BHRS), British Cardiovascular Society (BCS), British Heart Valve Society (BHVS) and British Society for Echocardiography (BSE).** *J Antimicrob Chemother.* 2015; **70**(2): 325–59.
PubMed Abstract | Publisher Full Text
15. Downey BC, Juselius WE, Pandian NG, *et al.*: **Incidence and significance of pacemaker and implantable cardioverter-defibrillator lead masses discovered during transesophageal echocardiography.** *Pacing Clin Electrophysiol.* 2011; **34**(6): 679–83.
PubMed Abstract | Publisher Full Text
16. F Tanis W, Budde RP, van der Bilt IA, *et al.*: **Novel imaging strategies for the detection of prosthetic heart valve obstruction and endocarditis.** *Neth Heart J.* 2016; **24**(2): 96–107.
PubMed Abstract | Publisher Full Text | Free Full Text | F1000 Recommendation
17. Liu YW, Tsai WC, Lin CC, *et al.*: **Usefulness of real-time three-dimensional echocardiography for diagnosis of infective endocarditis.** *Scand Cardiovasc J.* 2009; **43**(5): 318–23.
PubMed Abstract | Publisher Full Text
18. F Berdejo J, Shibayama K, Harada K, *et al.*: **Evaluation of vegetation size and its relationship with embolism in infective endocarditis: a real-time 3-dimensional transesophageal echocardiography study.** *Circ Cardiovasc Imaging.* 2014; **7**(1): 149–54.
PubMed Abstract | Publisher Full Text | F1000 Recommendation
19. Lang RM, Tsang W, Weinert L, *et al.*: **Valvular heart disease. The value of 3-dimensional echocardiography.** *J Am Coll Cardiol.* 2011; **58**(19): 1933–44.
PubMed Abstract | Publisher Full Text
20. F Nishimura RA, Otto CM, Bonow RO, *et al.*: **2014 AHA/ACC Guideline for the Management of Patients With Valvular Heart Disease: a report of the American College of Cardiology/American Heart Association Task Force on Practice Guidelines.** *Circulation.* 2014; **129**(23): e521–643.
PubMed Abstract | Publisher Full Text | F1000 Recommendation
21. F Bruun NE, Habib G, Thuny F, *et al.*: **Cardiac imaging in infectious endocarditis.** *Eur Heart J.* 2014; **35**(10): 624–32.
PubMed Abstract | Publisher Full Text | F1000 Recommendation
22. F Feuchtner GM, Stolzmann P, Dichtl W, *et al.*: **Multislice computed tomography in infective endocarditis: comparison with transesophageal echocardiography and intraoperative findings.** *J Am Coll Cardiol.* 2009; **53**(5): 436–44.
PubMed Abstract | Publisher Full Text | F1000 Recommendation
23. F Habets J, Tanis W, van Herwerden LA, *et al.*: **Cardiac computed tomography angiography results in diagnostic and therapeutic change in prosthetic heart valve endocarditis.** *Int J Cardiovasc Imaging.* 2014; **30**(2): 377–87.
PubMed Abstract | Publisher Full Text | F1000 Recommendation

24. F Kouijzer IJ, Vos FJ, Janssen MJ, *et al.*: **The value of ^{18}F-FDG PET/CT in diagnosing infectious endocarditis.** *Eur J Nucl Med Mol Imaging.* 2013; **40**(7): 1102–7.
PubMed Abstract | Publisher Full Text | F1000 Recommendation

25. F Pizzi MN, Roque A, Fernández-Hidalgo N, *et al.*: **Improving the Diagnosis of Infective Endocarditis in Prosthetic Valves and Intracardiac Devices With ^{18}F-Fluordeoxyglucose Positron Emission Tomography/Computed Tomography Angiography: Initial Results at an Infective Endocarditis Referral Center.** *Circulation.* 2015; **132**(12): 1113–26.
PubMed Abstract | Publisher Full Text | F1000 Recommendation

26. Vos FJ, Kullberg BJ, Sturm PD, *et al.*: **Metastatic infectious disease and clinical outcome in *Staphylococcus aureus* and Streptococcus species bacteremia.** *Medicine (Baltimore).* 2012; **91**(2): 86–94.
PubMed Abstract | Publisher Full Text

27. F Granados U, Fuster D, Pericas JM, *et al.*: **Diagnostic Accuracy of ^{18}F-FDG PET/CT in Infective Endocarditis and Implantable Cardiac Electronic Device Infection: A Cross-Sectional Study.** *J Nucl Med.* 2016; **57**(11): 1726–32.
PubMed Abstract | Publisher Full Text | F1000 Recommendation

28. Erba PA, Conti U, Lazzeri E, *et al.*: **Added value of ^{99m}Tc-HMPAO-labeled leukocyte SPECT/CT in the characterization and management of patients with infectious endocarditis.** *J Nucl Med.* 2012; **53**(8): 1235–43.
PubMed Abstract | Publisher Full Text

29. F Hyafil F, Rouzet F, Lepage L, *et al.*: **Role of radiolabelled leucocyte scintigraphy in patients with a suspicion of prosthetic valve endocarditis and inconclusive echocardiography.** *Eur Heart J Cardiovasc Imaging.* 2013; **14**(6): 586–94.
PubMed Abstract | Publisher Full Text | F1000 Recommendation

30. F Rouzet F, Chequer R, Benali K, *et al.*: **Respective performance of ^{18}F-FDG PET and radiolabeled leukocyte scintigraphy for the diagnosis of prosthetic valve endocarditis.** *J Nucl Med.* 2014; **55**(12): 1980–5.
PubMed Abstract | Publisher Full Text | F1000 Recommendation

Open Peer Review

Current Peer Review Status: ✔ ✔

Editorial Note on the Review Process

Faculty Reviews are review articles written by the prestigious Members of Faculty Opinions. The articles are commissioned and peer reviewed before publication to ensure that the final, published version is comprehensive and accessible. The reviewers who approved the final version are listed with their names and affiliations.

The reviewers who approved this article are:

Version 1

1. **Francois Rouzet**
   Department of Nuclear Medicine, Bichat-Claude Bernard Hospital, AP-HP, Paris, France
   Competing Interests: No competing interests were disclosed.
2. **Andrzej Kutarski**
   Department of Cardiology, Medical University of Lublin, Lublin, Poland
   Competing Interests: No competing interests were disclosed.

The benefits of publishing with F1000Research:

- Your article is published within days, with no editorial bias
- You can publish traditional articles, null/negative results, case reports, data notes and more
- The peer review process is transparent and collaborative
- Your article is indexed in PubMed after passing peer review
- Dedicated customer support at every stage

For pre-submission enquiries, contact research@f1000.com

F1000Research